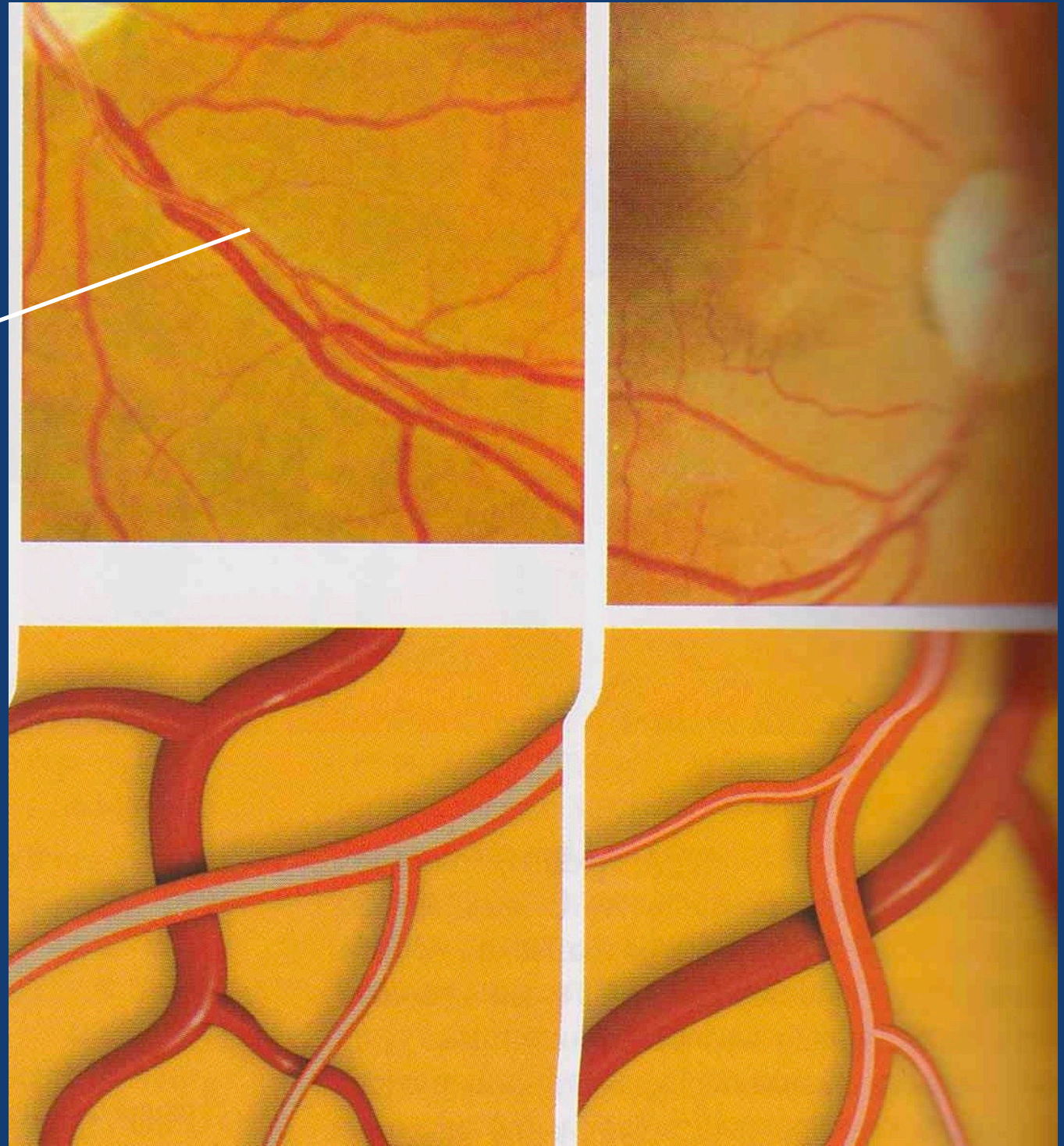
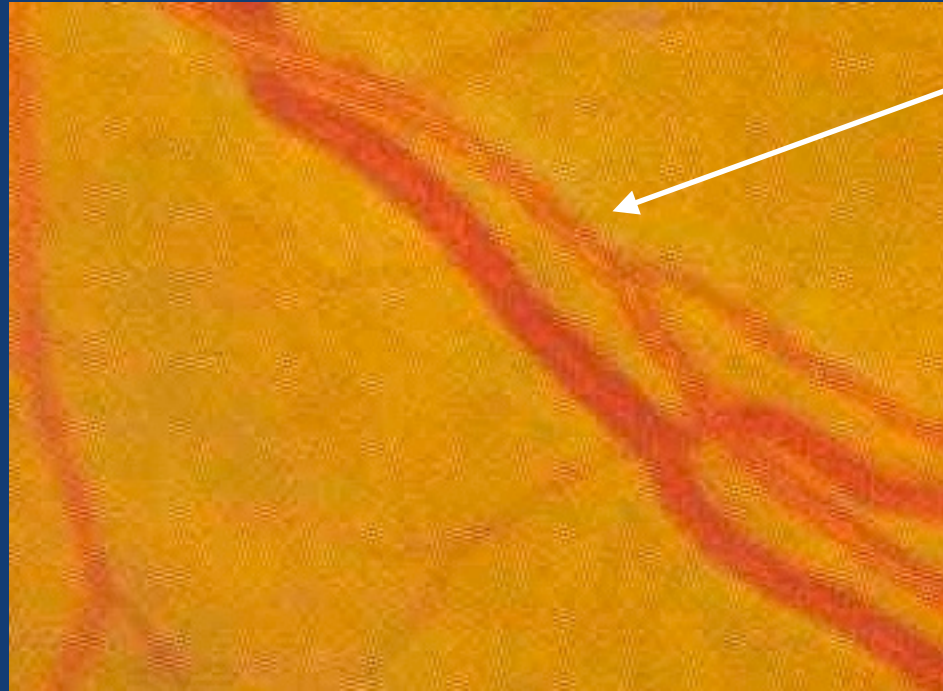


# Artériosclérose **stade 1**



Rétrissement artériel  
segmentaire avec reflet cuivré